

THE BRAIN HABIT

BRIDGING THE CONSCIOUS AND UNCONSCIOUS MIND

Mary ET Boyle, Ph. D.

Department of Cognitive Science

UCSD

Who has da control?



Dictate
behavior



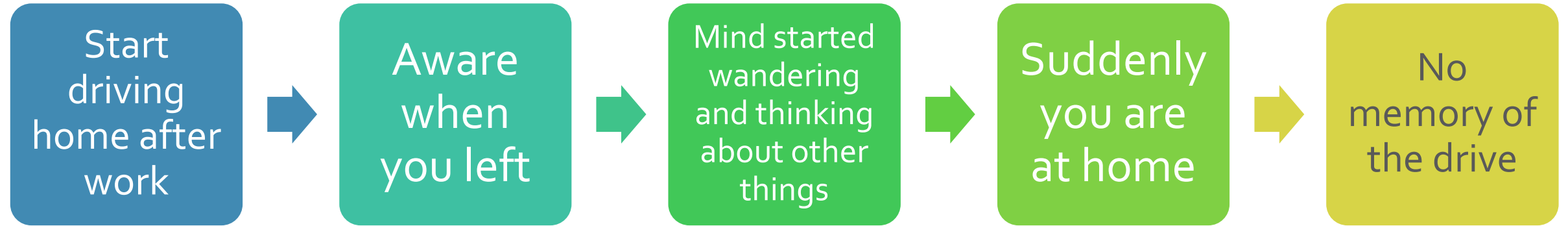Voluntary
behavior



Involuntary
behavior

How conscious and aware is one of behavior?

How did I get here? What did I do?



The essence of a habit.

On ***auto-pilot!***

Once you have learned something so well, you stop paying attention to it and thinking about it.

What does it all mean to you?

How are habits
different from other
types of learning?

How do habits
form?

Why are they so
hard to break?

Which behaviors turn
into habits?

Characteristics of Habits

Learned

- Experience dependent plasticity

Repeat

- Behaviors performed repeatedly

Automatic

- Nonconscious behavior

Ordered

- Stimulus driven structured sequence

Routine

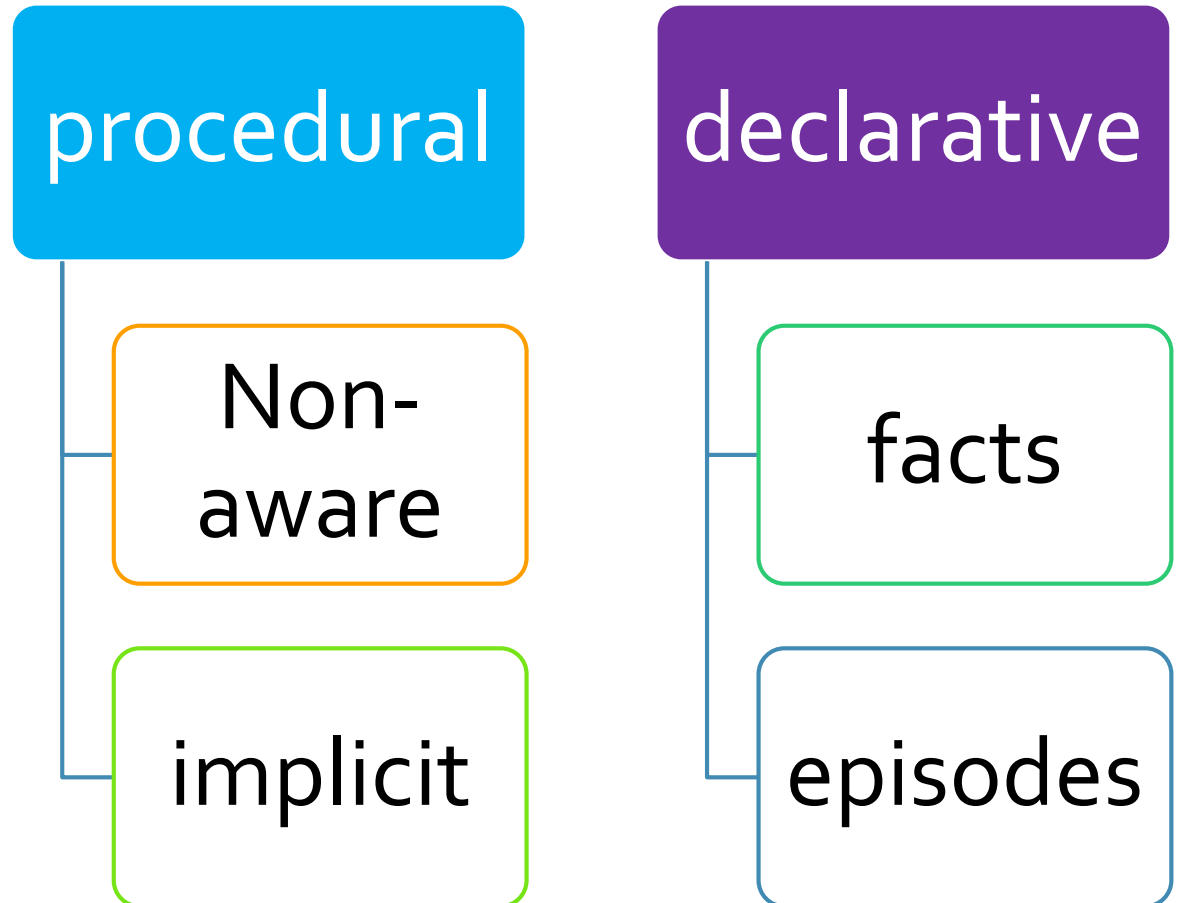
- Cognitive & Motor

habits

Learning → experience dependent plasticity

Habit is the most effective teacher of all things.
—Pliny

We are what we repeatedly do. Excellence, then, is not an act, but a habit.
—Aristotle



The story of E. P.

“....at home in Playa del Rey, preparing for dinner, when his wife mentioned that their son, Michael, was coming over. “Who’s Michael?” Eugene asked. “Your child,” said his wife, Beverly. “You know, the one we raised?” Eugene looked at her blankly. “Who is that?” he asked.”

The next day, Eugene started vomiting and writhing with stomach cramps. Within twenty-four hours, his dehydration was so pronounced that a panicked Beverly took him to the emergency room.

His temperature started rising, hitting 105 degrees as he sweated a yellow halo of perspiration onto the hospital’s sheets. He became delirious, then violent, yelling and pushing when nurses tried to insert an IV into his arm.

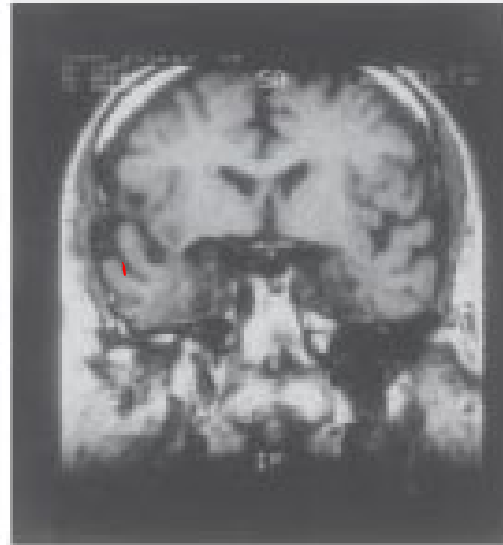
Only after sedation was a physician able to ... extract a few drops of cerebrospinal fluid.”

“The fluid surrounding the brain and spinal nerves is a barrier against infection and injury. In healthy individuals, it is clear and quick flowing, moving with an almost silky rush through a needle. The sample from Eugene’s spine was cloudy and dripped out sluggishly, as if filled with microscopic grit. When the results came back from the laboratory, Eugene’s physicians learned why he was ill: He was suffering from **viral encephalitis**, a disease caused by a relatively harmless virus that produces cold sores, fever blisters, and mild infections on the skin. In *rare cases*, however, the virus can make its way into the brain, inflicting **catastrophic damage** as it chews through the delicate folds of tissue where our thoughts, dreams—and according to some, souls—reside.”

Duhigg, C. (2012) *The Power of Habit: Why We Do What We Do in Life and Business* ”

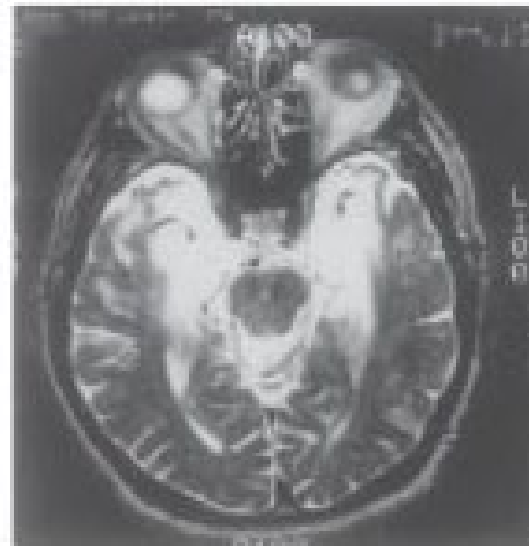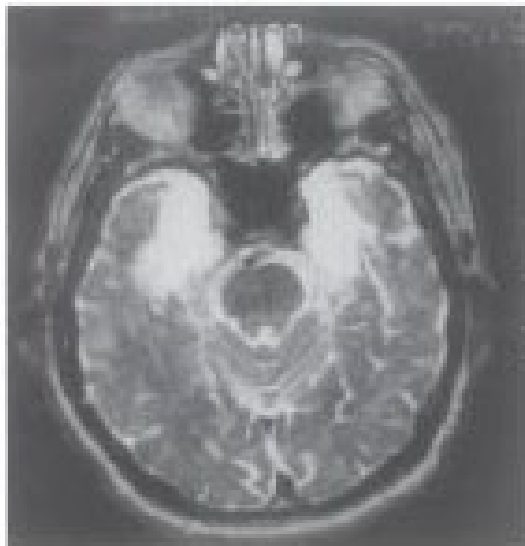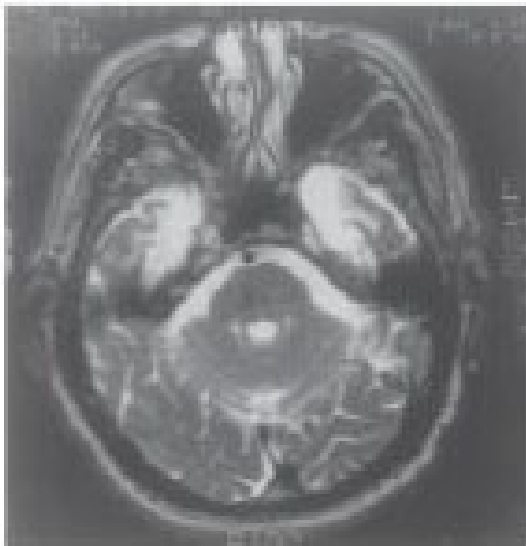
Damage to **patient EP's** brain: bilateral medial temporal lobe.

- **amygdala** and the **entire hippocampal region**.



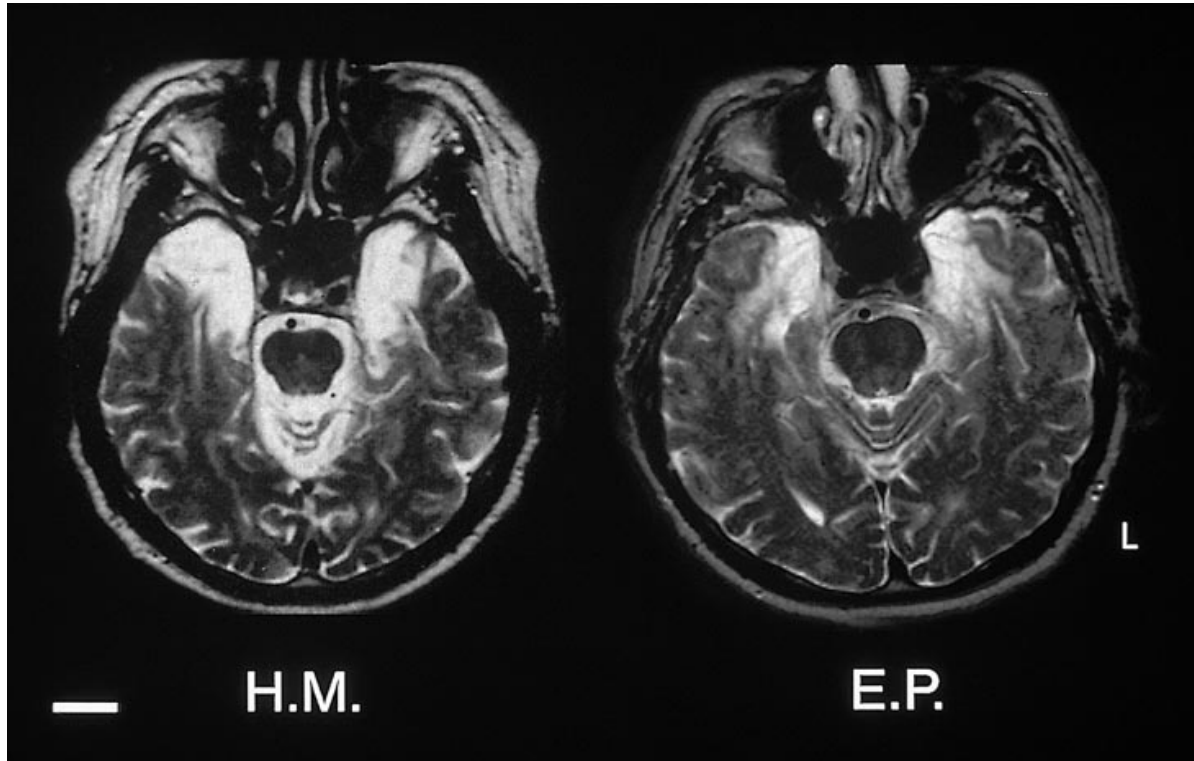
Coronal T_1 -weighted image at the level of the amygdala.

Damaged tissue is indicated by a dark signal.

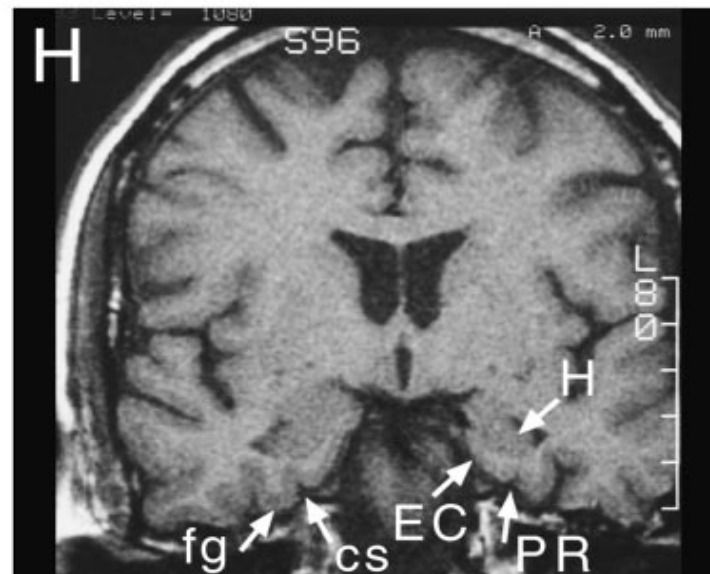
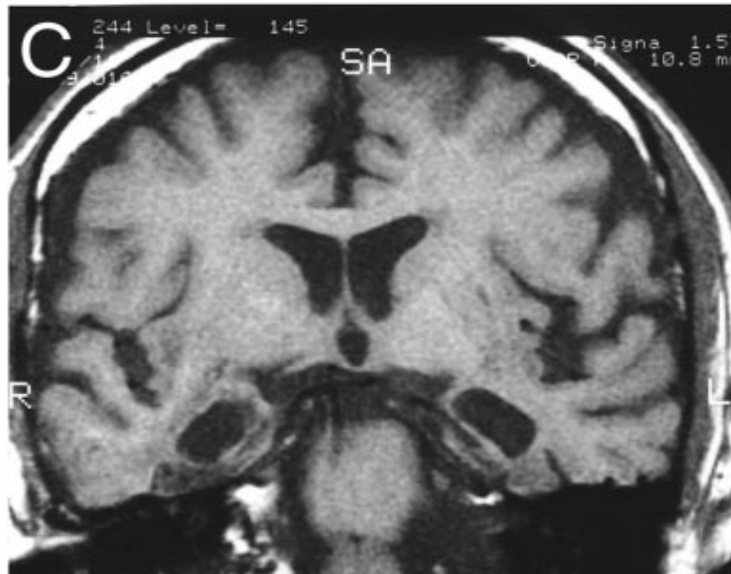
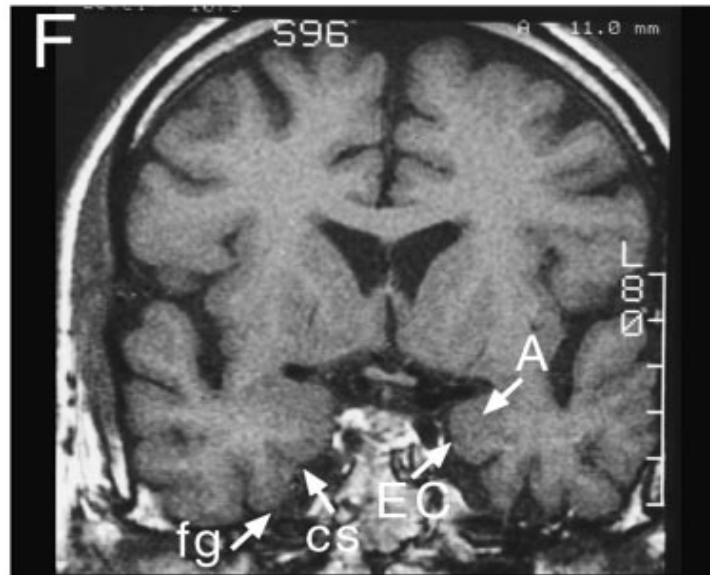
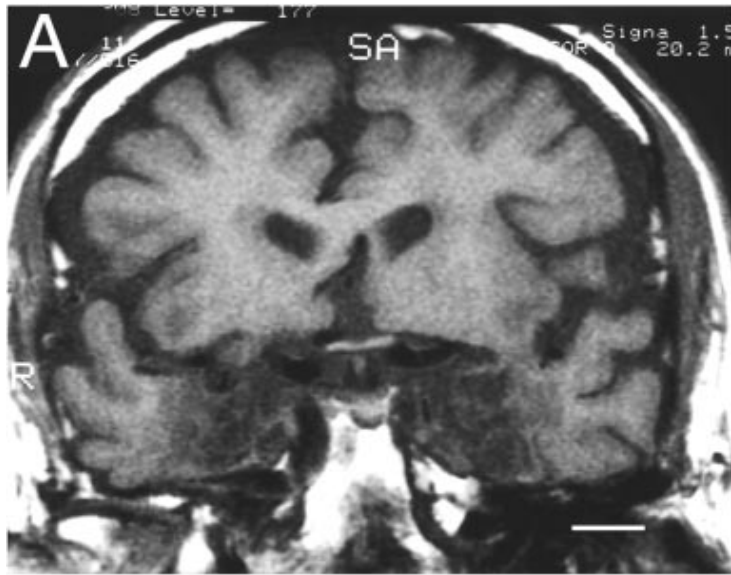


T_2 -weighted axial images through the temporal lobe. The images are continuous 5-mm sections (with 2.5-mm gaps) and are arranged from ventral to dorsal (left to right).

Damaged tissue is indicated by a bright signal.



T2-weighted axial MRIs of patients E. P. (*right*) and H. M. (*left*), through the level of the temporal lobes. Damaged tissue is indicated by bright signal. Images are oriented according to radiological convention (the right side of the brain is on the *left side* of the image). Both patients sustained extensive damage to medial temporal lobe structures. Scale bar, 2 cm



T1-weighted coronal images through the temporal lobes of E. P. (*left*) and 74-year-old control (*right*).

Damaged tissue in E. P. is indicated by dark signal.

In panel A: the amygdala, rostral hippocampus, parahippocampal gyrus (comprising the entorhinal and perirhinal cortices at this level), and the fusiform gyrus are extensively damaged bilaterally.

In C, nothing remains of the intraventricular portion of the hippocampal formation except perhaps a thin remnant of tissue bilaterally. The damage to the fusiform gyrus can be seen on both sides. Entorhinal and perirhinal cortices are severely compromised bilaterally.

Scale bar: A, 2 cm

E. P. couldn't remember which day of the week it was, the names of his doctors or nurses, no matter how many times they introduced themselves.

E. P. didn't seem to remember their friends or family members. He had trouble following conversations...

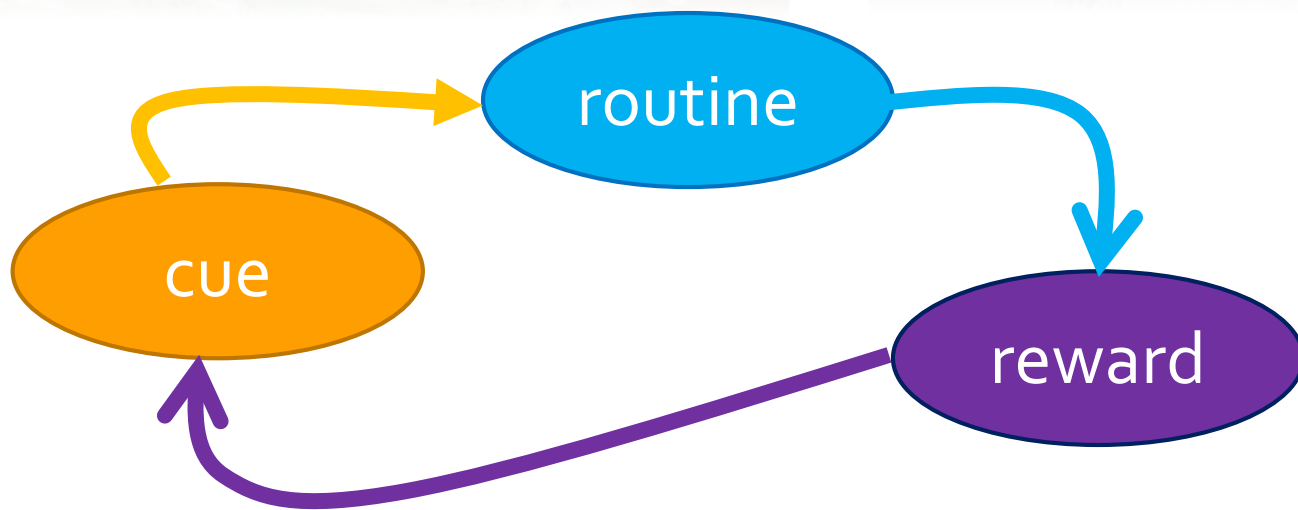
Some mornings he would get out of bed, walk to the kitchen, cook himself bacon and eggs, then climb back under the covers and turn on the radio.

Forty minutes later he would repeat the same actions, again and again!



CLICK HERE
& WATCH video






“The doctors had warned Beverly that she would need to monitor Eugene constantly.

If he ever got lost, they said, he would never be able to find his way home. But one morning, while she was getting dressed, Eugene slipped out the front door. ...”

C. Duhigg



To test if Eugene was forming new habits, Squire devised an experiment. He took sixteen different objects—bits of plastic and brightly colored pieces of toys—and glued them to cardboard rectangles. He then divided them into eight pairs: choice A and choice B. In each pairing, one piece of cardboard, chosen at random, had a sticker placed on the bottom that read “correct.”^{1.21}

Eugene was seated at a table, given a pair of objects, and asked to choose one. Next, he was told to turn over his choice to see if there was a “correct” sticker underneath. This is a common way to measure memory. Since there are only sixteen objects, and they are always presented in the same eight pairings, most people can memorize which item is “correct” after a few rounds. Monkeys can memorize all the “correct” items after eight to ten days.

But as the weeks passed, Eugene's performance improved. After twenty-eight days of training, Eugene was choosing the "correct" object 85 percent of the time. At thirty-six days, he was right 95 percent of the time. After one test, Eugene looked at the researcher, bewildered by his success.

"How am I doing this?" he asked her.

"Tell me what is going on in your head," the researcher said. "Do you say to yourself, 'I remember seeing that one'?"

"No," Eugene said. "It's here somehow or another"—he pointed to his head—"and the hand goes for it."



LETTERS

Robust habit learning in the absence of awareness and independent of the medial temporal lobe

Peter J. Bayley¹, Jennifer C. Frascino¹ & Larry R. Squire^{1,2,3,4}

Habit memory is thought to involve slowly acquired associations between stimuli and responses and to depend on the basal ganglia¹. Habit memory has been well studied in experimental animals but is poorly understood in humans because of their strong tendency to acquire information as conscious (declarative) knowledge. Here we show that humans have a robust capacity for gradual trial-and-error learning that operates outside awareness for what is learned and independently of the medial temporal lobe.

We tested two patients with large medial temporal lobe lesions and no capacity for declarative memory. Both patients gradually acquired a standard eight-pair object discrimination task over many weeks but at the start of each session could not describe the task, the instructions or the objects. **The acquired knowledge was rigidly organized, and performance collapsed when the task format was altered.**

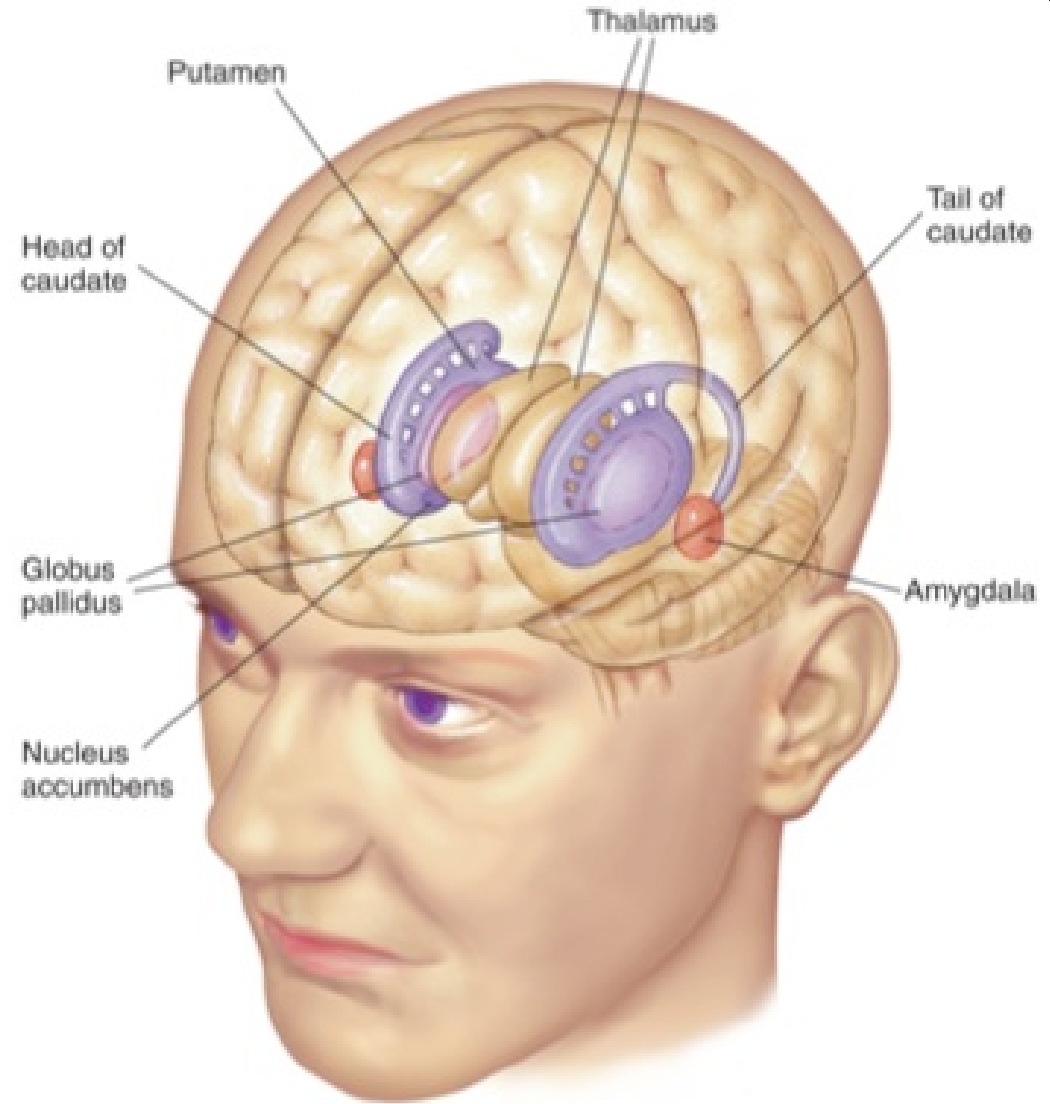
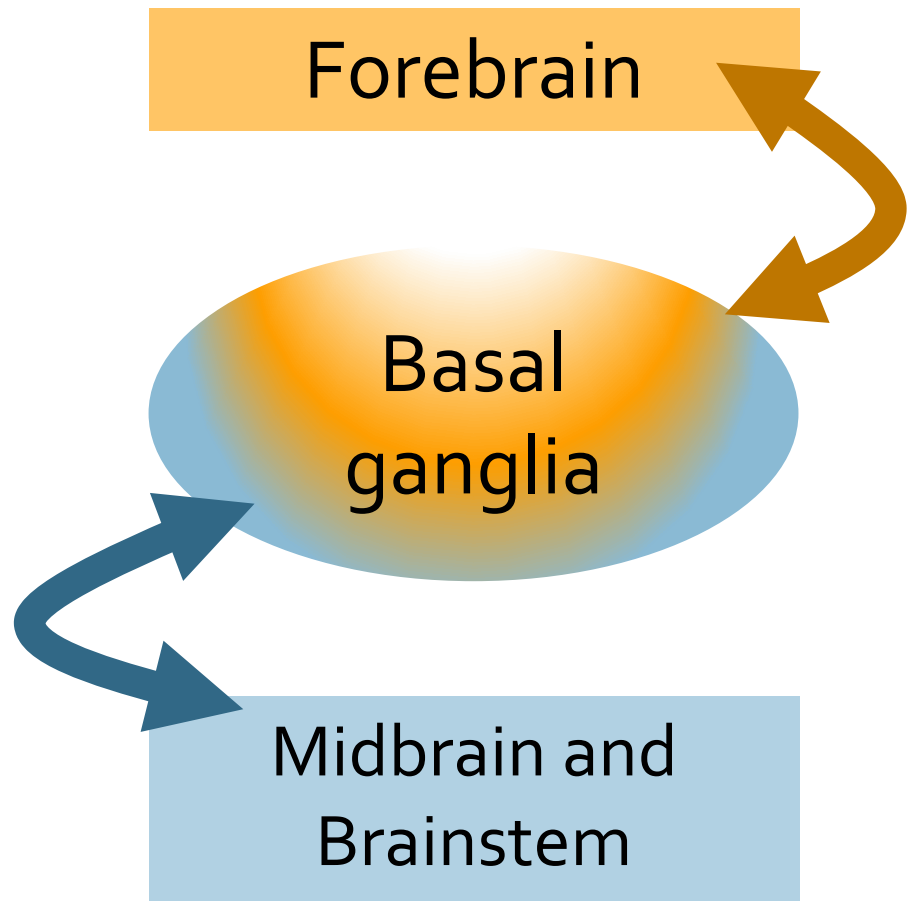
Habit memory

- Slowly acquired associations between stimuli and response
- Trial and error learning
- Performance based

Dependent on Basal ganglia

- Operates outside of awareness
- Trial and error learning
- Ridged organization

Linking thought and movement **simultaneously!**



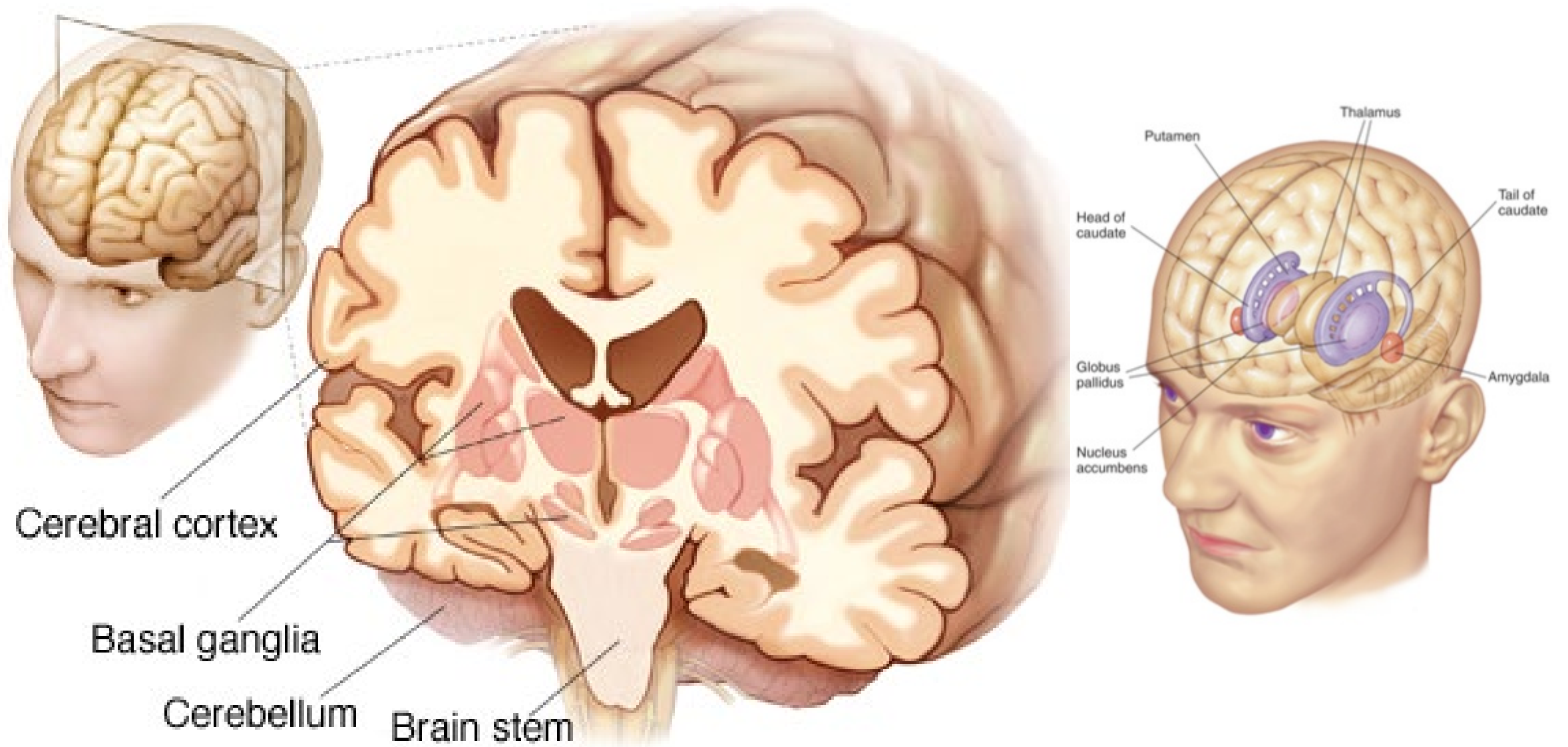
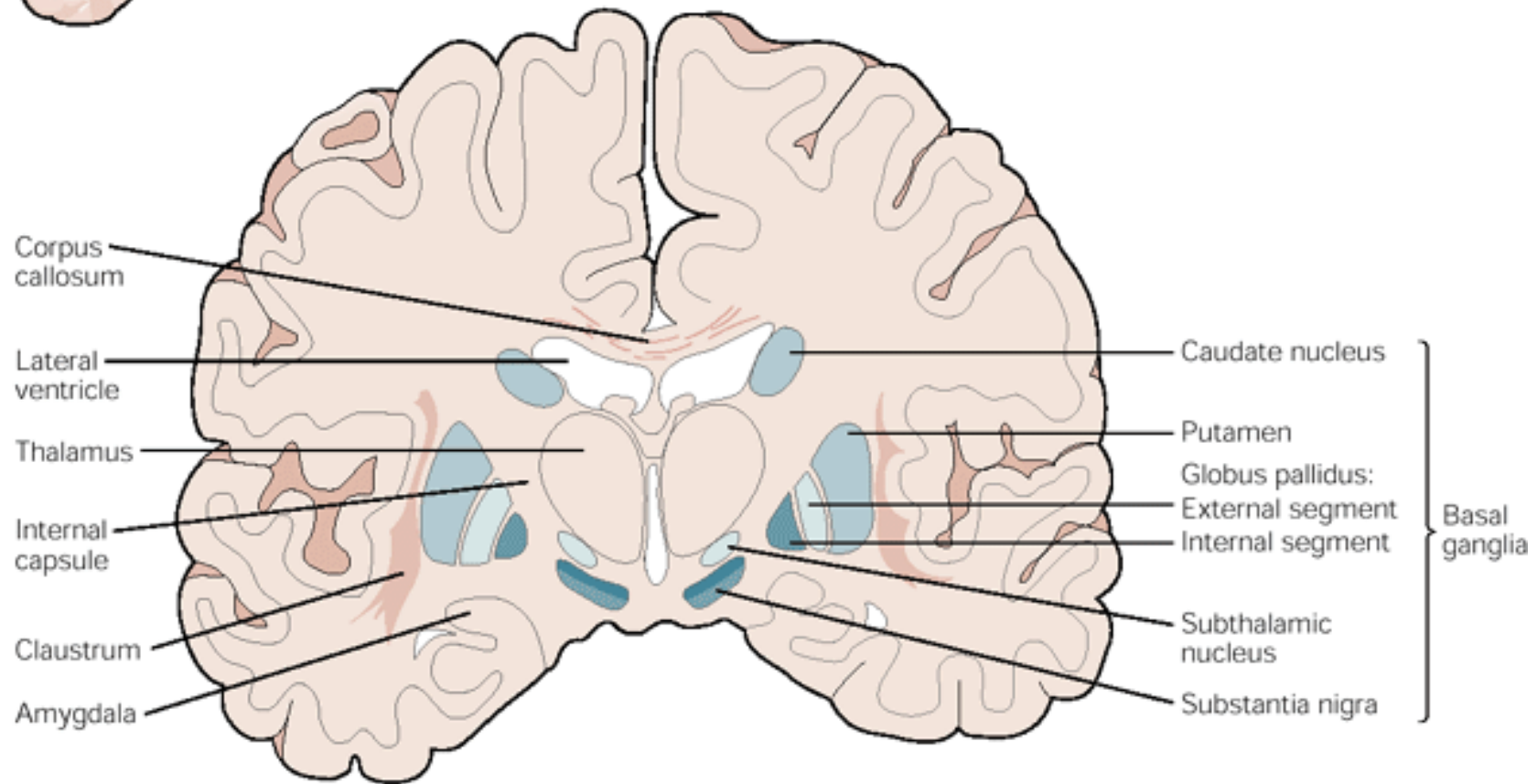
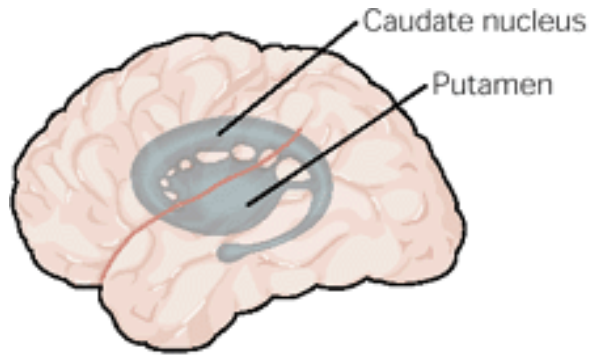
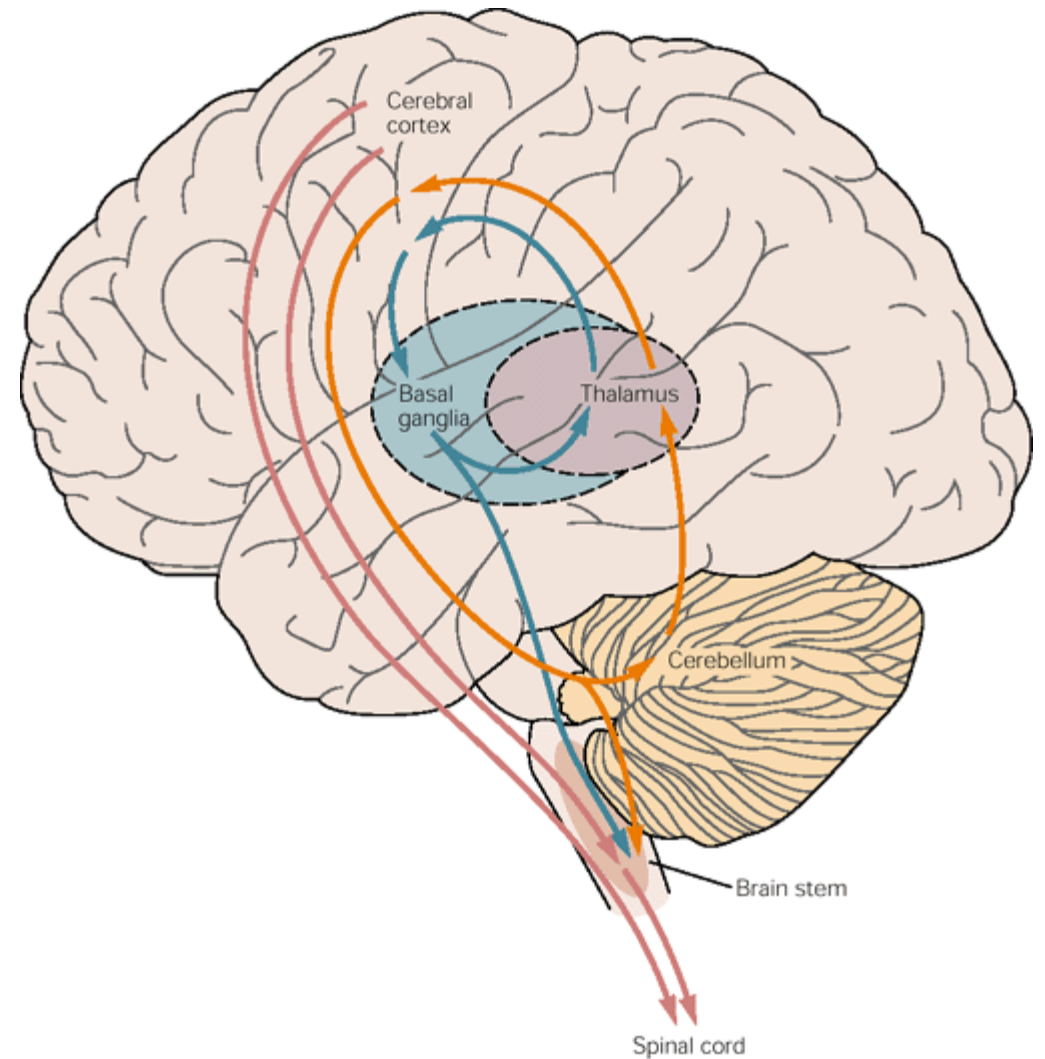
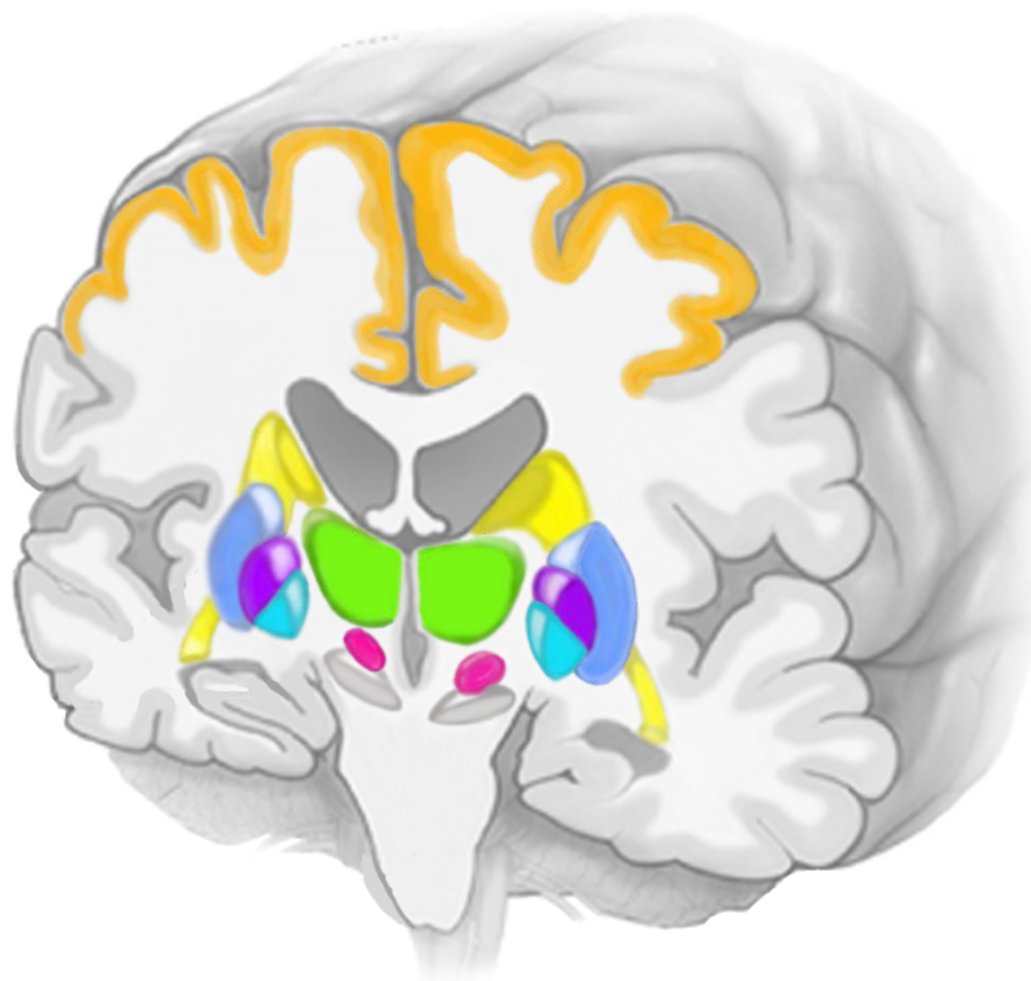
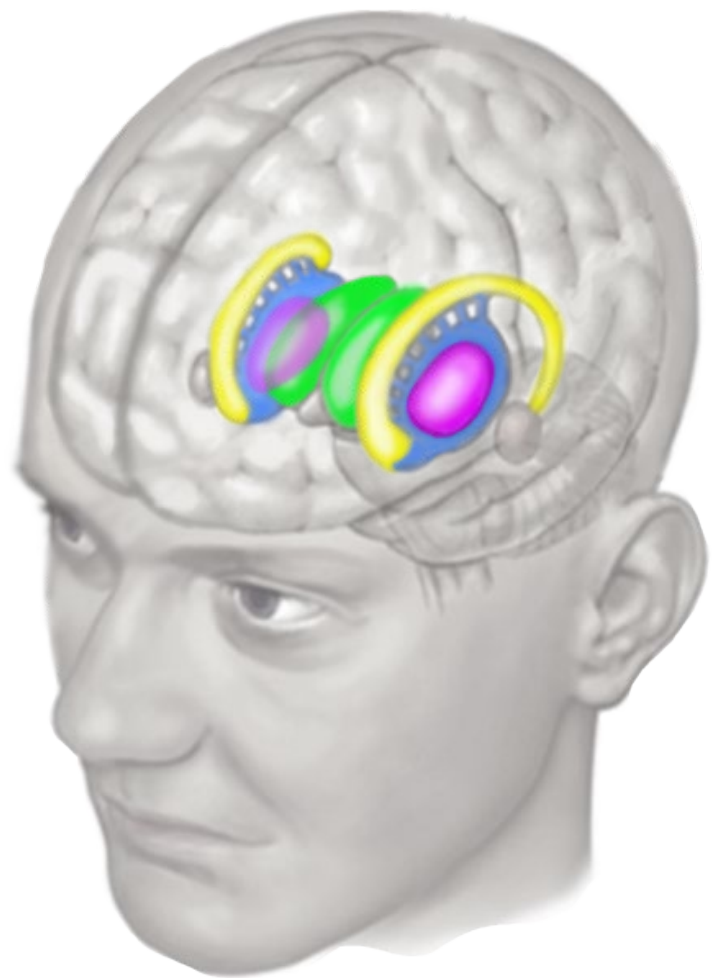


Image from Mayo Clinic



1. Have a major role in normal voluntary movement.
2. BG does not have direct input or output connections with the spinal cord.
3. BG nuclei receive primary input from the cerebral cortex and send output to the brain stem and, via the thalamus, back to the prefrontal, premotor, and motor cortices.
4. The motor functions of the basal ganglia are therefore mediated, in large part, by motor areas of the frontal cortex.





Largest subcortical brain structure

“ The basal ganglia receive inputs from the neocortex and, by way of their output nuclei, the basal ganglia nuclei project massively to thalamic nuclei, which in turn project to the frontal cortex. This anatomy means the basal ganglia are in a prime position to influence the executive functions of the forebrain, such as planning for movement and even cognitive behaviors. ”

